



A Forgotten Disease in Children: Lemierre Syndrome

Çocuklarda Unutulan Bir Hastalık: Lemierre Sendromu

© Zekiye Aybüke Şen Ersöz¹, © Nazan Ülgen Tekerek², © Alper Köker², © Oğuz Dursun², © Tuğçe Tural Kara³, © Nilgün Erkek⁴

¹Akdeniz University Faculty of Medicine, Department of Pediatrics, Antalya, Turkey

²Akdeniz University Faculty of Medicine, Department of Pediatric Intensive Care, Antalya, Turkey

³Akdeniz University Faculty of Medicine, Department of Pediatric Infectious Disease, Antalya, Turkey

⁴Akdeniz University Faculty of Medicine, Department of Pediatric Emergency, Antalya, Turkey

Abstract

Lemierre's syndrome is a life-threatening disease following oropharyngeal infections. A thirteen-year-old female patient presented with fatigue, facial edema, and shortness of breath. In the computerized tomographic examination, an abscessed area extends from the left temporal region to the bilateral submandibular area and the submental area from the para calvarial area. The right jugular vein calibration was thin and there was an intraluminal thrombus in the right innominate vein. The patient, who developed respiratory failure and whose mouth opening could not be achieved due to the abscess, was admitted to the pediatric intensive care unit after an emergency tracheostomy was performed. Thoracostomy and pericardiectomy were performed due to pleural and pericardial effusion. Lemierre's syndrome was diagnosed because of this clinical picture, which includes sepsis and jugular vein thrombosis after oropharyngeal infection. Early diagnosis, initiation of appropriate antibiotics and abscess drainage are important for Lemierre syndrome. A timely and multidisciplinary approach will be lifesaving.

Keywords: Lemierre, children thrombus, abscess

Öz

Lemierre sendromu, orofaringeal enfeksiyonları takiben gelişen hayatı tehdit eden bir hastalıktır. On üç yaşında kız hasta halsizlik, yüzde ödem ve nefes darlığı yakınmaları ile başvurdu. Bilgisayarlı tomografi incelemesinde sol temporal parakalvarial bölgeden başlayarak bilateral submandibular bölgeden submental bölgeye uzanan apse görünümü, sağ jugüler ven kalibrasyonu incelmış ve sağ innominat vende intraluminal trombüs mevcuttu. Solunum yetmezliği gelişen ve apse nedeniyle ağız açıklığı sağlanamayan hasta acil trakeostomi yapıldıktan sonra çocuk yoğun bakım ünitesine yatırıldı. Plevral ve perikardiyal efüzyon nedeniyle torasentez ve perikardiyosentez yapıldı. Orofaringeal enfeksiyon sonrası sepsis ve jugüler ven trombozunu içeren bu klinik tablo nedeniyle Lemierre sendromu tanısı konuldu. Lemierre sendromumu için erken tanı, uygun antibiyotik başlanması ve apse drenajı oldukça önemlidir. Zamanında ve multidisipliner bir yaklaşım hayat kurtarıcıdır.

Anahtar Kelimeler: Lemierre, çocuk trombüs, apse

Introduction

Lemierre's syndrome is a life-threatening disease characterized by septicemia and internal jugular thrombosis with septic emboli, following oropharyngeal infections.^{1,2} It was described by Andre Lemierre in 1936. Lemierre syndrome is also known as the "forgotten disease", because of its rarity. The incidence of this disease is 3.6 cases per million per year. The most common microorganism causing Lemierre's syndrome is the Gram-negative anaerobic rod

Fusobacterium necrophorum.³ *Bacteroides*, *Streptococcus* group B and C, *Streptococcus oralis*, *Staphylococcus epidermitis*, *Enterococcus* and *Proteus mirabilis* may also be involved.⁴ Today, morbidity and mortality have gradually decreased after the use of appropriate antibiotics.⁵

In this case report, we describe a patient who exhibited Lemierre's syndrome atypically with pericardial and pleural effusion after treatment for a dental abscess and was followed up in the intensive care unit by placing an emergency tracheostomy due to tracheal deviation is presented.

Address for Correspondence/Yazışma Adresi: Nazan Ülgen Tekerek, Akdeniz University Faculty of Medicine, Department of Pediatric Intensive Care, Antalya, Turkey

E-mail: nazanulgen@hotmail.com **ORCID ID:** orcid.org/0000-0002-4577-1488

Received/Geliş Tarihi: 03.07.2023 **Accepted/Kabul Tarihi:** 03.10.2023



©Copyright 2024 by Society of Pediatric Emergency and Intensive Care Medicine Journal of Pediatric Emergency and Pediatric Intensive Care published by Galenos Yayınevi. This article is distributed under the terms of the Creative Commons Attribution-NonCommercial (CC BY-NC) International License.

Case Report

A thirteen-year-old female patient presented with fatigue, facial edema, and shortness of breath. She had been treated with intravenous ceftriaxone and clindamycin for five days and had complained of pain in her left upper molar for ten days before admission.

On admission, the patient was in poor general condition, she had tachypnea (70/min) and left hemiface edema. Laboratory tests were: Hemoglobin 9.7 g/dL, leukocyte count 26,420/mm³ (neutrophils 85%), platelet count 729,000/mm³, and C-reactive protein 191 mg/L. On computed tomography of the patient's brain, cervical spine, and chest, an abscessed area extended from the left temporal region to the bilateral submandibular area and the submental area from the paracalvarial area. The abscess has opened to the floor of the mouth and the right aryepiglottic fold was obliterated. The collection area extended inferiorly on the right, deviated the trachea to the left, and passed between the jugular vein and the carotid artery toward the mediastinal area (Figure 1). The calibration of the right jugular vein was thin and there was an intraluminal thrombus in the right innominate vein. There was a 2.5 cm pericardial effusion and a 6 cm pleural effusion in the right hemithorax with an associated atelectatic lung area. The patient, who developed respiratory failure and was unable to open his mouth due to the abscess, was admitted to the pediatric intensive care unit after an emergency tracheostomy was performed. An echocardiogram showed normal left ventricular ejection fraction and pericardial effusion. Empirical antibiotic therapy was a combination of piperacillin-tazobactam, vancomycin, and metronidazole. Intravenous immunoglobulin (IVIG) treatment was given for sepsis. Colchicine and non-steroidal anti-inflammatory drugs were initiated for pericardial effusion. Inotropic therapy (noradrenaline) was started for hypotension and discontinued during follow-up. Tube thoracostomy and tube pericardiotomy were performed due to pleural and pericardial effusion. The pleural fluid was exudate according to biochemical criteria. The patient was evaluated for mediastinitis and surgical abscess drainage was performed for the abscess in the mediasten. *Streptococcus mitis* and *Candida dubliniensis* were isolated from pleural fluid culture and treatment was revised as meropenem, vancomycin, metronidazole, and caspofungin. Lemierre's syndrome was diagnosed because of this clinical status, which includes sepsis and jugular vein thrombosis after oropharyngeal infection. She was anticoagulated with enoxaparin sodium. Immunoglobulin levels and lymphocyte subgroup analysis were normally concluded before IVIG treatment. Colchicine and non-steroidal anti-inflammatory drugs were initiated

for pericardial effusion. Inotropic therapy was started for hypotension and discontinued during follow-up. Tube thoracostomy and tube pericardiotomy were performed for pleural and pericardial effusion. The pleural fluid was evaluated as exudative according to biochemical criteria. The patient was evaluated for mediastinitis and surgical abscess drainage was performed for the mediastinal abscess. *Streptococcus mitis* and *Candida dubliniensis* were isolated from the pleural fluid culture and treatment was changed to meropenem, vancomycin, metronidazole, and caspofungin. Lemierre's syndrome was diagnosed based on this clinical status, which includes sepsis and jugular vein thrombosis after oropharyngeal infection. She was anticoagulated with enoxaparin sodium. Immunoglobulin levels and lymphocyte subgroup analysis were normally concluded before IVIG treatment.

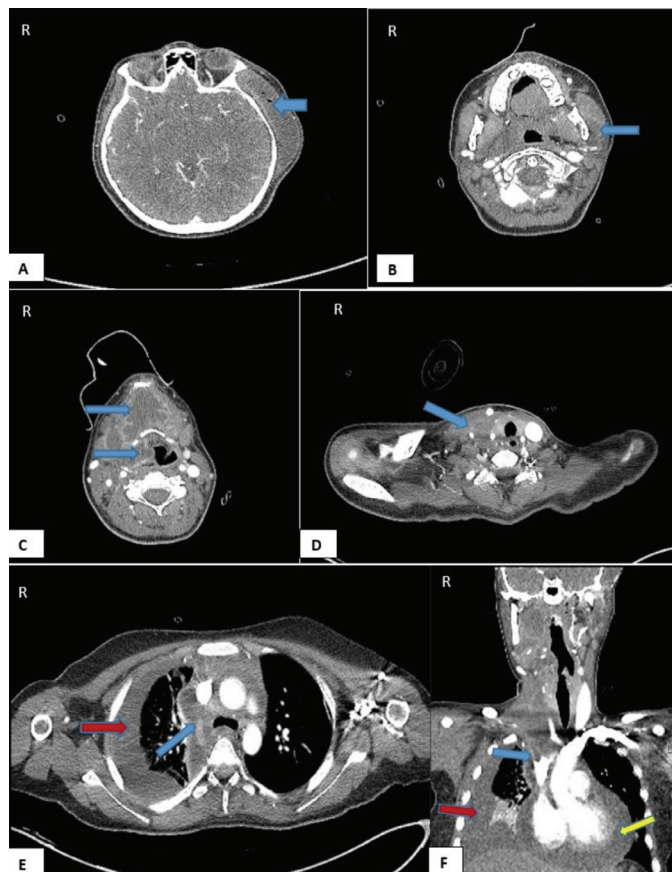


Figure 1. Abscess localization and accompanying findings in computed tomography. Abscess obliterating the aryepiglottic fossa is seen in the left temporal region paracalvarial area (A; blue arrow), around the left mandibular ramus (B; blue arrow), and in the right parapharyngeal area. The collection area crosses the submental and submandibular areas in a horseshoe shape (C; blue arrows) and deviates the trachea slightly to the left on the right side (D; blue arrow). The abscess area extends to the mediastinal area between the jugular vein and the carotid artery on the right side (E; blue arrow). Compression-related thinning in the right jugular vein calibration, intraluminal thrombus image in the innominate vein (F; blue arrow). Pericardial effusion (F; yellow arrow), pleural effusion and atelectatic lung fields (E, F; red arrow) accompanying abscess

Clinical response was achieved after surgical intervention and antibiotic therapy. Thoracic and pericardial tubes were removed on day 6. She was decannulated and discharged from the hospital 28 days after admission. Control ultrasound was normal without thrombus.

Discussion

Lemierre's syndrome is a condition in which an oropharyngeal infection progresses to thrombophlebitis of the internal jugular vein and septic embolization.⁶ Lemierre primarily affects young adults. The primary source of infection may be odontogenic infection, mastoiditis, parotitis, sinusitis, otitis media, and skin or subcutaneous tissue infections.^{7,8} Clinical findings include fever, cervical lymphadenopathy, pain, and stiffness of the neck from 4 to 5 days after the onset of pharyngitis. Edema and pain at the angle of the mandible and parallel to the sternocleidomastoid muscle indicate involvement of the parapharyngeal space. Septic embolism of the jugular vein mainly affects the lungs. Pulmonary involvement may present with severe chest pain, shortness of breath, and hemoptysis. Respiratory distress is present in the majority of cases.⁹⁻¹¹ The diagnosis was based on the following criteria: 1-primary oropharyngeal infection, 2-septicemia with at least one culture growth, 3-clinical or radiological evidence of cranial or cervical vein thrombosis and 4-secondary metastatic abscesses. In our case, Lemierre syndrome was diagnosed based on a history of dental infection, leukocytosis in laboratory tests, elevated C-reactive protein, abscess on computed tomography scan, a thrombus in the right jugular vein, and a pericardial and pleural effusion due to a mediastinal abscess.

Although causal bacteria are isolated in 80% of cases, many organisms including *Staphylococci*, *Streptococci*, *Fusobacterium* and anaerobic Gram-negative *Bacilli*, have been reported in etiology.^{12,13}

The first line of treatment is intravenous antimicrobial therapy, with coverage for anaerobes, staphylococci, and streptococci. β -lactam/ β -lactamase inhibitor, clindamycin, and metronidazole have been suggested for *Fusobacterium* species. Piperacillin-tazobactam and carbapenems are widely used in antibiotic treatment in cases with a severe clinical course.¹⁴ In this case, *Streptococcus mitis* was isolated from a blood culture. Piperacillin-tazobactam, vancomycin, and metronidazole were started in our case who was followed up in the pediatric intensive care unit, and then piperacillin-tazobactam was revised as meropenem.

The routine use of anticoagulation in Lemierre's syndrome cannot be recommended because of limited data.^{11,15} Our patient was anticoagulated with enoxaparin sodium.

Conclusion

Considering the high mortality rate of Lemierre's syndrome, early diagnosis, initiation of appropriate antibiotics and abscess drainage are important. Prolonged oropharyngeal infection and worsening of symptoms in a young healthy adolescent should suggest Lemierre's syndrome and should be investigated for thrombosis and septic embolism. A timely and multidisciplinary approach to Lemierre's syndrome will be lifesaving.

Ethics

Informed Consent: Informed consent was obtained from the patient's family.

Authorship Contributions

Concept: Z.A.Ş.E., N.Ü.T., O.D., N.E., Design: N.Ü.T., O.D., Data Collection or Processing: Z.A.Ş.E., N.Ü.T., Analysis or Interpretation: Z.A.Ş.E., N.Ü.T., A.K., T.T.K., Literature Search: Z.A.Ş.E., N.Ü.T., Writing: Z.A.Ş.E., N.Ü.T.

Conflict of Interest: No conflict of interest was declared by the authors.

Financial Disclosure: The authors declared that this study received no financial support.

References

1. Noh HJ, Freitas CA, Souza Rde P, Simoes JC, Kosugi EM. Lemierre syndrome: a rare complication of pharyngotonsillitis. *Braz J Otorhinolaryngol.* 2015;81:568-70.
2. Miyamoto S, Toi T, Kotani R, Iwakami T, Yamada S, et al. Lemierre Syndrome Associated with Ipsilateral Recurrent Laryngeal Nerve Palsy: A Case Report and Review. *NMC Case Rep J.* 2016;3:53-7.
3. Pol H, Guerby P, Duazo Cassin L, Chantalat E, Tournemire A, et al. Dangerous Liaisons: Pelvic Variant of Lemierre Syndrome by Right Common Iliac Vein Thrombophlebitis After Sexual Intercourse. *J Low Genit Tract Dis.* 2017;21:e37-e9.
4. Vargiami EG, Zafeiriou DI. Eponym: the Lemierre syndrome. *Eur J Pediatr.* 2010;169:411-4.
5. Riordan T. Human infection with *Fusobacterium necrophorum* (Necrobacillosis), with a focus on Lemierre's syndrome. *Clin Microbiol Rev.* 2007;20:622-59.
6. Civgin E, Toprak U, Parlak S, Ozer H. Fissuration of vertebral artery mycotic aneurysm due to Lemierre syndrome. *Diagn Interv Imaging.* 2018;99:43-5.
7. Silva DR, Gazzana MB, Albaneze R, Dalcin Pde T, Vidart J, et al. Septic pulmonary embolism secondary to jugular thrombophlebitis: a case of Lemierre's syndrome. *J Bras Pneumol.* 2008;34:1079-83.
8. De Giorgi A, Fabbian F, Molino C, Misurati E, Tiseo R, et al. Pulmonary embolism and internal jugular vein thrombosis as evocative clues of Lemierre's syndrome: A case report and review of the literature. *World J Clin Cases.* 2017;5:112-8.
9. Lemierre A. On certain septicemias due to anaerobic organisms. *Lancet.* 1936;227:701-3.

10. Goldenberg NA, Knapp-Clevenger R, Hays T, Manco-Johnson MJ. Lemierre's and Lemierre's-like syndromes in children: survival and thromboembolic outcomes. *Pediatrics*. 2005;116:e543-8.
11. Handa GI, Bertuzzo GS, Muller KS, Dambinski AC, Buzingnani VZ, et al. Lemierre syndrome: case report. *J Vasc Bras*. 2010;9:82-5.
12. Chirinos JA, Lichtstein DM, Garcia J, Tamariz LJ. The evolution of Lemierre syndrome: report of 2 cases and review of the literature. *Medicine (Baltimore)*. 2002;81:458-65.
13. Dool H, Soetekouw R, van Zanten M, Grooters E. Lemierre's syndrome: three cases and a review. *Eur Arch Otorhinolaryngol* 2005;262:651-4.
14. Johannesen KM, Bodtger U. Lemierre's syndrome: current perspectives on diagnosis and management. *Infect Drug Resist*. 2016;9:221-7.
15. Kuppalli K, Livorsi D, Talati NJ, Osborn M. Lemierre's syndrome due to *Fusobacterium necrophorum*. *Lancet Infect Dis*. 2012;12:808-15.